

CASE REPORT

Q2 A Case of Intractable Hyperhidrosis in Spinal Cord Q3 Injury: Role of Stellate Ganglion Block

Q7 Q4 Soun Sheen ^{a,*}, Hemant Kalia ^b, Victoria Kung ^b

Q5 ^a University of Rochester, United States

^b Rochester Regional Health System, United States

Keywords: Stellate ganglion block, Autonomic dysreflexia, Hyperhidrosis

Q1 1. Introduction

Patients with spinal cord injury (SCI), specifically with injuries at T6 or higher, lack descending sympathetic control, resulting in denervation hypersensitivity of the adrenergic receptors below the lesion.¹ Therefore, a noxious stimulus originating below the level of the injury can trigger an exaggerated sympathetic response which can result in a potentially life-threatening hypertensive crisis known as autonomic dysreflexia (AD).^{2,3} It is often accompanied by other symptoms including hyperhidrosis, usually above the injury, from the exaggerated sympathetic innervation of the eccrine glands.⁴ Hyperhidrosis may also manifest on its own and present exclusively below the injury or diffusely, although the exact pathophysiology remains unclear.^{2,4}

Although hyperhidrosis in SCI is often insidious and self-limiting, it can also be idiopathic or intractable in the setting of an underlying stimulus that is difficult to identify or control.⁵ There is also a lack of standard treatment guideline for hyperhidrosis in patients with SCI. We describe a case of successful use of stellate ganglion blocks for intractable hyperhidrosis in a patient with complete cervical SCI presenting with acute thoracic discitis.

2. Case description

A 58-year-old female with history of C7 ASIA A (American Spinal Injury Association classification) SCI from a traumatic C6–C7 spinal fracture in 1974

presented to the hospital with profuse sweating episodes without reported antecedent illness, trauma, or other new signs and symptoms. All vital signs were within normal ranges, and she did not report any pain. Further work-up revealed T7-T8 discitis and osteomyelitis (Fig. 1). There was no indication for a neurosurgical intervention and the patient was managed conservatively with a prolonged course of antibiotics. However, patient continued to experience multiple disabling diffuse hyperhidrosis, up to 50 episodes daily. Patient was no longer able to self-transfer to her power wheelchair or perform self-care. After failing multiple medications including propranolol, tizanidine, and clonidine patch, patient underwent a stellate ganglion block under ultrasound guidance.

A high frequency ultrasound probe was placed at C6, important structures including carotid artery, transverse process of C6, internal jugular vein, inferior thyroid artery, and longus colli muscle were clearly identified. Color flow and doppler function as used to identify the vascular structures. A 22G 3.5inch echogenic needle was used using in plane technique to target the prevertebral fascia between carotid artery and the tip of C6 anterior tubercle (Fig. 2). A total of 5 ml of preservative-free 0.25% bupivacaine was injected with greater than 75% reduction in the intensity and frequency of her symptoms. She was then able to participate in her rehabilitation therapies and discharged home at her prior level of function. Patient continued to report relief for 3 months after discharge and underwent repeat stellate ganglion blocks with continued relief

Q6 * Corresponding author.

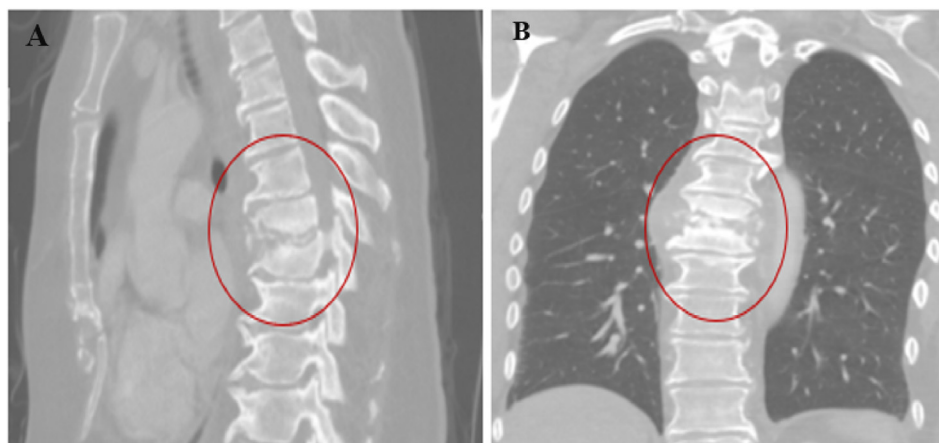


Fig. 1. Sagittal (A) and coronal (B) views of the spine demonstrating T7-T8 discitis.

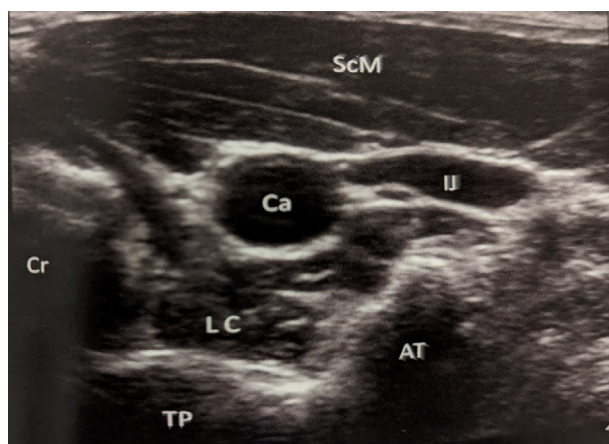


Fig. 2. Ultrasound image of stellate ganglion at C6. Ca: Carotid artery, TP: Transverse Process, LC: Longus coli, IJ: Internal jugular vein, AT: Anterior tubercle, Cr: Cricoids, ScM: Sternocleidomastoid muscle.

for up to 3 months with each procedure. We alternated between left and right with equal relief.

3. Discussion

This case presents a unique treatment approach for intractable hyperhidrosis in patients with SCI. Stellate ganglion is a collection of inferior cervical and first thoracic sympathetic ganglions found anterior to the neck of the first rib.⁶ Stellate ganglion block (SGB) has been safely used for many conditions. Although the exact underlying mechanism by which SGB modulates hyperhidrosis is unclear, it is thought to involve vasodilation and central sympathetic blockade regardless of the laterality.^{7,8} SGB may also modulate nerve growth factor and norepinephrine levels, decreasing sympathetic nerve sprouting.^{7,9}

The procedure can be performed under ultrasound or fluoroscopic, in oblique or anterior parat-

racheal approach, guidance. A local anesthetic of choice can be injected at the C6 level. An injection below the C6 level is not recommended due to higher risks of vascular puncture of the unprotected vertebral artery.¹⁰ A transient, post-injection Horner syndrome can confirm the successful sympathetic blockade.

In this case, we successfully managed intractable hyperhidrosis secondary to acute thoracic discitis below the level of injury in a complete cervical SCI patient. SGB provides a safe sympathetic blockade for the treatment of hyperhidrosis while also offering a potential role in the treatment of certain sympathetically mediated autonomic dysfunctions in SCI patients.

Conflict of interest

Hemant Kalia MD, MPH, FIPP: Consultant Abbott, Omnia Medical, Averitas Pharmaceuticals.

References

1. Eldahan KC, Rabchevsky AG. Autonomic dysreflexia after spinal cord injury: systemic pathophysiology and methods of management. *Auton Neurosci*. 2018;209:59–70.
2. Krassioukov AV, Karlsson AK, Wecht JM, et al. Assessment of autonomic dysfunction following spinal cord injury: rationale for additions to International Standards for Neurological Assessment. *J Rehabil Res Dev*. 2007;44(1):103–112. <https://doi.org/10.1682/jrrd.2005.10.0159>.
3. Kirshblum S, Donovan J, Nieves J, Gonzalez P, Cuccurullo SJ, Luciano L. Spinal cord injury. In: Cuccurullo SJ, Lee J, Bagay L, eds. *Physical medicine and rehabilitation board review*. Demos Medical; 2020.
4. Fast A. Reflex sweating in patients with spinal cord injury: a review. *Arch Phys Med Rehabil*. 1977;58(10):435–437.
5. Andersen LS, Biering-Sørensen F, Müller PG, Jensen IL, Aggerbeck B. The prevalence of hyperhidrosis in patients with spinal cord injuries and an evaluation of the effect of dextropropoxyphene hydrochloride in therapy. *Paraplegia*. 1992;30(3):184–191. <https://doi.org/10.1038/sc.1992.53>.

6. Epter RS. Stellate ganglion block. In: Diwan S, Staats PS, eds. *Atlas of pain medicine procedures*. McGraw-Hill; 2015.
7. Walega DR, Rubin LH, Banuvar S, Shulman LP, Maki PM. Effects of stellate ganglion block on vasomotor symptoms: findings from a randomized controlled clinical trial in postmenopausal women. *Menopause*. 2014;21(8):807–814. <https://doi.org/10.1097/GME.000000000000194>.
8. Lipov EG, Lipov S, Joshi JR, Santucci VD, Slavin KV, Beck Vigue SG. Stellate ganglion block may relieve hot flashes by interrupting the sympathetic nervous system. *Med Hypotheses*. 2007;69(4):758–763. <https://doi.org/10.1016/j.mehy.2007.01.082>.
9. Guirguis M, Abdelmalak J, Jusino E, Hansen MR, Girgis GE. Stellate ganglion block for the treatment of hot flashes in patients with breast cancer: a literature review. *Ochsner J*. 2015;15(2):162–169.
10. Chang KV, Wu WT, Özçakar L. Ultrasound-guided interventions of the cervical spine and nerves. *Phys Med Rehabil Clin*. 2018;29(1):93–103. <https://doi.org/10.1016/j.pmr.2017.08.008>.

AUTHOR QUERY FORM

Journal: ACMRHD Article Number: 1104	Please share your corrections or revision and any artwork related corrections to Digital common site. E-mail: publishing.services@cs.bepress.com
---	---

Dear Author,

Please check your proof carefully and mark all corrections at the appropriate place in the proof (e.g., by using on-screen annotation in the PDF file) or compile them in a separate list. **It is crucial that you NOT make direct edits to the PDF using the editing tools as doing so could lead us to overlook your desired changes.** Note: if you opt to annotate the file with software other than Adobe Reader then please also highlight the appropriate place in the PDF file. To ensure fast publication of your paper please return your corrections within 48 hours.

Any queries or remarks that have arisen during the processing of your manuscript are listed below and highlighted by flags in the proof.

Location in article	Query / Remark: Click on the Q link to find the query's location in text Please insert your reply or correction at the corresponding line in the proof
Q1	Please provide accept date for this article.
Q2	Please provide an abstract for this article.
Q3	Correctly acknowledging the primary funders and grant IDs of your research is important to ensure compliance with funder policies. Please make sure that funders are mentioned accordingly.
Q4	Please check whether the designated corresponding author is correct, and amend if necessary.
Q5	The country name has been inserted for the affiliations. Please check, and correct if necessary.
Q6	Please provide email address for the corresponding author.
Q7	Please confirm that given names and surnames have been identified correctly and are presented in the desired order and please carefully verify the spelling of all authors' names.

Thank you for your assistance.